



# Thyroid Eye Disease (TED)

## Clinical Documentation Guide

This guide may help document common TED symptomatology required by most payors, such as Clinical Activity Score (CAS). Thorough clinical documentation can help streamline the payor access process for your patients.

### Included in this guide:

- Instructions for completing CAS section of Clinical Documentation Form
- TED Clinical Documentation Form
- TED Glossary


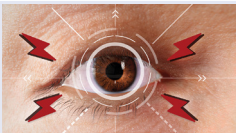
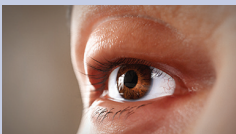


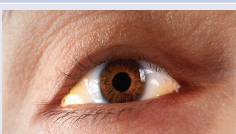

**Submitting a prior authorization (PA) is a critical step to help patients access TED treatment.**

**Clinical Documentation Checklist:** Ensure all required clinical documentation is included in chart notes and submitted with the prior authorization

- Diagnosis of Thyroid Eye Disease or Graves' ophthalmopathy (or other thyroid-associated ophthalmopathy) including ICD-10 code(s)
- CAS and patient condition on examination
- Onset and severity of symptoms
- Previous treatments and other conditions:
  - Has the patient tried, failed, and/or been contraindicated for steroid therapy?
  - Has the patient been diagnosed with Graves' disease?
- Thyroid labs (T3 and T4) *some payors may require (free T3 and free T4) or (thyroid stimulating hormone or TSH)*
- Prescriber specialty and information

# Documenting TED symptomatology—Clinical Activity Score (CAS)

CAS is an indicator of inflammatory TED signs and symptoms. It is important to accurately capture a patient's CAS, as payors may require a CAS.<sup>1-3</sup>

TYPICAL SIGNS AND SYMPTOMS ASSESSED IN CAS <sup>1,2</sup>		PTS	QUESTIONS TO ASK PATIENTS
1	Spontaneous orbital pain 	1	<ul style="list-style-type: none"> <li>• Have you ever felt pain behind your eye?</li> <li>• Have you ever felt pressure behind your eye?</li> <li>• Do you ever have deep pain behind your eye—like a headache? When was the last time you felt this? How often?</li> </ul>
2	Gaze-evoked orbital pain 	1	<ul style="list-style-type: none"> <li>• Do you ever feel discomfort, pain, or tenderness in or behind your eye when you look in different directions (up, down, left, right)?</li> </ul>
3	Eyelid swelling 	1	<ul style="list-style-type: none"> <li>• Have you had episodes of eyelid swelling? How long do they last? How often do they occur?</li> <li>• How often do you have some degree of eyelid swelling?</li> <li>• Is there a difference from when you wake up and later in the day?</li> </ul>
4	Eyelid erythema 	1	<ul style="list-style-type: none"> <li>• Do your eyes or eyelids ever feel swollen or look red?</li> <li>• How does the time of day impact your eyes?</li> </ul>
5	Conjunctival redness 	1	<ul style="list-style-type: none"> <li>• Are there ever times when you have redness in the whites of your eyes?</li> <li>• Is it allergies, or not?</li> <li>• Do you use eye drops to help with irritation?</li> </ul>
6	Chemosis 	1	<ul style="list-style-type: none"> <li>• Do you ever feel congested?</li> <li>• Have you ever observed that you have eye secretion or areas that are swollen and look blistered?</li> </ul>
7	Inflammation of caruncle or plica 	1	<ul style="list-style-type: none"> <li>• Do you ever notice swelling in or around the red area in the corner of your eye nearest your nose (sometimes referred to as caruncle or plica)?</li> </ul>
For baseline CAS, total lines 1-7			
8	Increase of $\geq 2$ mm in proptosis	1	<ul style="list-style-type: none"> <li>• [clinical evaluation] [Consider referring to Hertel exophthalmometry normal values]</li> </ul>
9	Decreased eye movements $>8^\circ$ in any direction	1	<ul style="list-style-type: none"> <li>• [clinical evaluation]</li> </ul>
10	Decrease in acuity $\geq 1$ Snellen line	1	<ul style="list-style-type: none"> <li>• [clinical evaluation]</li> </ul>
For follow-up CAS, total lines 1-10			

TED can threaten patients' vision. Identifying these signs and symptoms early can benefit patients and reduce the impact of the disease.<sup>4,5</sup>

# The Clinical Activity Score (CAS) is a tool designed to evaluate inflammatory signs and symptoms that are often characteristic of TED.<sup>1</sup>

## How to compute the CAS<sup>2</sup>

STEP 1: One point is given for each sign or symptom.

STEP 2: Add up the points. **For example:**

Spontaneous orbital pain	1
Eyelid swelling	1
Eyelid erythema	1
Conjunctival redness	1
<b>Total</b>	<b>CAS = 4</b>

STEP 3: Reassess during follow-up for changes from baseline.

## In addition, ask your patients:

- Is there anything you are no longer able to do because of symptoms?
- Do you have any photos that show your eyes looking differently than they do today?

---

The CAS score alone should not be used to determine if treatment intervention is needed, but it is an important assessment that can add to the full evaluation of the patient's burden of disease.

## Quick tips for assessing TED:

- Assessment of TED signs and symptoms
  - Consider requesting and/or accepting patient eye photos for a baseline
- Measure eyelid retraction and proptosis<sup>1,6</sup>
- CAS assessment<sup>1</sup>
- Evaluate visual function, including color vision and diplopia<sup>4</sup>
- Assess the burden of disease on activities of daily living and self-confidence

# Clinical documentation of Thyroid Eye Disease (TED) signs and symptoms

Consider including this in the patient's medical record to monitor symptoms of disease activity

Patient name: \_\_\_\_\_ Date of birth: \_\_\_\_\_ (mm/dd/yyyy) Weight: \_\_\_\_\_ (lb) Date: \_\_\_\_\_ (mm/dd/yyyy)

## CLINICAL ACTIVITY SCORE<sup>1</sup>

### CLINICAL ACTIVITY SCORE<sup>1\*</sup>

The Clinical Activity Score (CAS) is a tool designed to evaluate inflammatory signs and symptoms that are often characteristic of TED, also known as Graves' orbitopathy. The score can be used as one part of the overall assessment of TED.

How to use CAS: 1 point is given for each sign or symptom. CAS ≥3 indicates inflammatory disease.		Baseline exam	Follow-up assessment
Date (mm/dd/yyyy)		___/___/___	___/___/___
1	Spontaneous orbital pain		
2	Gaze-evoked orbital pain		
3	Eyelid swelling		
4	Eyelid erythema		
5	Conjunctival redness		
6	Chemosis		
7	Inflammation of caruncle or plica		
For baseline CAS, total lines 1-7			
8	Increase of ≥2 mm in proptosis		
9	Decreased eye movements >8° in any direction		
10	Decrease in acuity ≥1 Snellen line		
For follow-up CAS, total lines 1-10			

\*The CAS is a composite score with equal weighting of a number of factors; however, the factors may not be equal clinical weight to the patient or to the physician. While CAS is a useful tool for diagnosis and monitoring of patients, some patients may not present with characteristic signs of TED and may require additional evaluation.

### THYROID FUNCTION

Does the patient have stable thyroid levels?  Yes  No

Is the patient undergoing treatment to correct and/or maintain thyroid state?  Yes  No

Thyroid labs:

Free thyroxine (free T4) levels: \_\_\_\_\_

Free triiodothyronine (free T3) levels: \_\_\_\_\_

Patient name: \_\_\_\_\_ Date of birth: \_\_\_\_\_ Date: \_\_\_\_\_  
 (mm/dd/yyyy) (mm/dd/yyyy)

## SEVERITY OF TED SYMPTOMS<sup>2</sup>

To determine whether symptoms are mild, moderate, or severe/vision threatening, document sign and symptom changes with the American Thyroid Association® Graves' Orbitopathy Severity Assessment.

Fill in the information based on criteria used in the table below:	Lid retraction: _____	Proptosis: _____	Corneal exposure: _____
	Soft tissue involvement: _____	Diplopia: _____	Optic nerve status: _____

Grade*	Lid retraction	Soft tissues	Proptosis <sup>†</sup>	Diplopia	Corneal exposure	Optic nerve status
Mild	<2 mm	Mild involvement	<3 mm	Transient or absent	Absent	Normal
Moderate-to-severe	≥2 mm	Moderate or severe involvement	≥3 mm	Inconstant or constant	Mild	Normal
Sight threatening	—	—	—	—	Severe	Compression

Upper limits of normal: Measure degree of proptosis according to values below or any available patient baselines

African American	F/M = 23/24 mm
White	F/M = 19/21 mm
Asian	F/M = 16/17 mm (Thai) or 18.6 mm (Chinese)

The publisher for this copyrighted material is Mary Ann Liebert, Inc. publishers

Sources: Adapted from de Juan et al. (3) Sarinnapakorn et al. (4) Tsai et al. (5) and Baralena et al. (6).

\*Mild Graves' orbitopathy (GO): patients whose features of GO have only a minor impact on daily life, generally insufficient to justify immunosuppressive or surgical treatment. Moderate-to-severe GO: patients without sight-threatening GO whose eye disease has sufficient impact on daily life to justify the risks of immunosuppression (if active) or surgical intervention (if inactive). Sight-threatening GO: patients with dysthyroid optic neuropathy and/or corneal breakdown. This category warrants immediate intervention.<sup>7</sup>

<sup>†</sup>Proptosis refers to the variation compared to the upper limit of normal for each race/sex or the patient's baseline, if available.<sup>7</sup>

## DOCUMENTATION OF PREVIOUS TREATMENT(S)

Fill out the table below to document the patient's previous treatment(s) for TED.

	Date range	Results of treatment
Eye drops		
Steroids <input type="checkbox"/> Oral <input type="checkbox"/> IV Dose: _____		
Biologics		
Other		

## OTHER FACTORS

History of diabetes?  Yes  No

Inflammatory bowel disease?  Yes  No

Pregnant?  Yes  No

Birth control?  Yes  No

Graves' disease associated with TED?  Yes  No  Other \_\_\_\_\_

Physician signature: \_\_\_\_\_ Date: \_\_\_\_\_  
 (mm/dd/yyyy)

# TED Glossary

**Abduction:** movement of the eye away from the midline or nose, also known as lateral movement.

**Acuity or visual acuity:** the clarity or sharpness of vision.

**Adduction:** movement of the eye toward the midline or nose, also known as medial movement.

**Caruncle:** small pink, globular spot at the inner corner of the eye. See *Figure 1, A*.

**Chemosis:** swelling of the tissue that lines the eyelids and surface of the eye (or conjunctiva).

**Clinical Activity Score (CAS):** an assessment scale designed to evaluate the signs and symptoms characteristic of TED. Calculated by summing the signs and symptoms based on the 7- or 10-point CAS scale. CAS is commonly used in clinical trials and by payors.

**Compressive optic neuropathy (CON):** occurs when your optic (vision) nerve has been damaged from compression such as tumors, or by orbital inflammatory conditions, such as thyroid eye disease.

**Conjunctiva:** the mucous membrane that covers the front of the eye and lines the inside of the eyelids (surface of the eye).

**Conjunctival redness:** redness of the surface of the eye.

**Cornea:** clear dome over the iris.

**Diplopia:** double vision.

**Edema:** swelling.

**Erythema:** redness of the skin.

**Esotropia:** one eye deviates inward.

**Exotropia:** one eye deviates outward.

**Eyelid erythema:** redness of the eyelids.

**Eyelid retraction:** the upper or lower eyelid margins are drawn back from the normal position.

**Free T3:** “free” refers to unbound triiodothyronine (T3) in the blood. A free T3 test is often ordered to help diagnose hyperthyroidism. (Some payors may have specific thyroid lab requirements).

**Free T4:** “free” refers to unbound thyroxine (T4) in the blood.

**Gaze-evoked orbital pain:** pain in, on or around the eye, evoked by looking steadily or intently at something.

**Iris:** colored part of the eye.

**Ischemic optic neuropathy (ION):** a sudden loss of vision due to decreased or interrupted blood flow to the optic nerve.

**Lagophthalmos:** describes the incomplete or abnormal closure of the eyelids.

**Letter of medical necessity (LMN):** formal argument made by a physician to a payor to cover a certain test or treatment. Explains the physician’s rationale and clinical decision-making.

**Margin to reflex distance (MRD) measurement:** the measurement in millimeters from the light reflex on the patient’s cornea to the level of the center of the

upper-eyelid margin, with the patient gazing in the primary position.

**Oculus dexter (OD):** right eye.

**Oculus sinister (OS):** left eye.

**Oculus uterque (OU):** both eyes.

**Optic neuritis (ON):** inflammation of the optic nerve.

**Orbit:** bony cavity in the skull that houses the globe of the eye or eyeball, the muscles that move the eye (extraocular muscles), the lacrimal gland, and the blood vessels and nerves required to supply these structures.

**Photophobia:** extreme sensitivity to light.

**Plica:** vertical fold of conjunctiva that occupies the canthus (or either corner of the eye where the upper and lower eyelids meet) of the eye nearest the nose. See *Figure 1, B*.

**Proptosis or exophthalmos:** a medical term for bulging or protruding eyeballs.

**Sclera:** white part of the eye.

**Scleral show:** an anatomical condition in which the sclera area is visibly exaggerated due to constitutional, evolutive, or endocrine etiology.

**Spontaneous orbital pain:** sudden pain in, on, or around the eye.

**Strabismus or hypertropia:** misalignment of the eyes.

**Thyroid eye disease (TED):** an autoimmune disease in which the eye muscles and fatty tissue behind the eye become inflamed. This inflammation can push the eyes forward (“staring” or “bulging”) or cause the eyes and eyelids to become red and swollen.

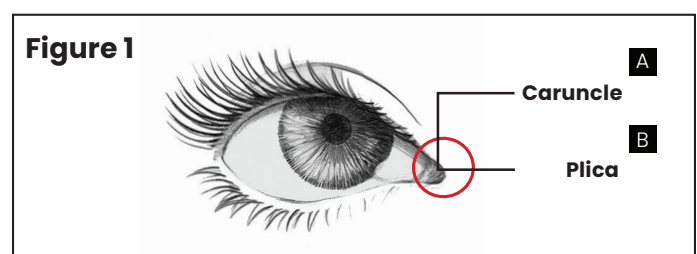
**Thyroid stimulating hormone (TSH):** a hormone released by the pituitary gland that stimulates the thyroid to release thyroid hormones.

**Thyroid stimulating immunoglobulin (TSI):** thyroid stimulating immunoglobulins are antibodies that play a role in thyroid regulation.

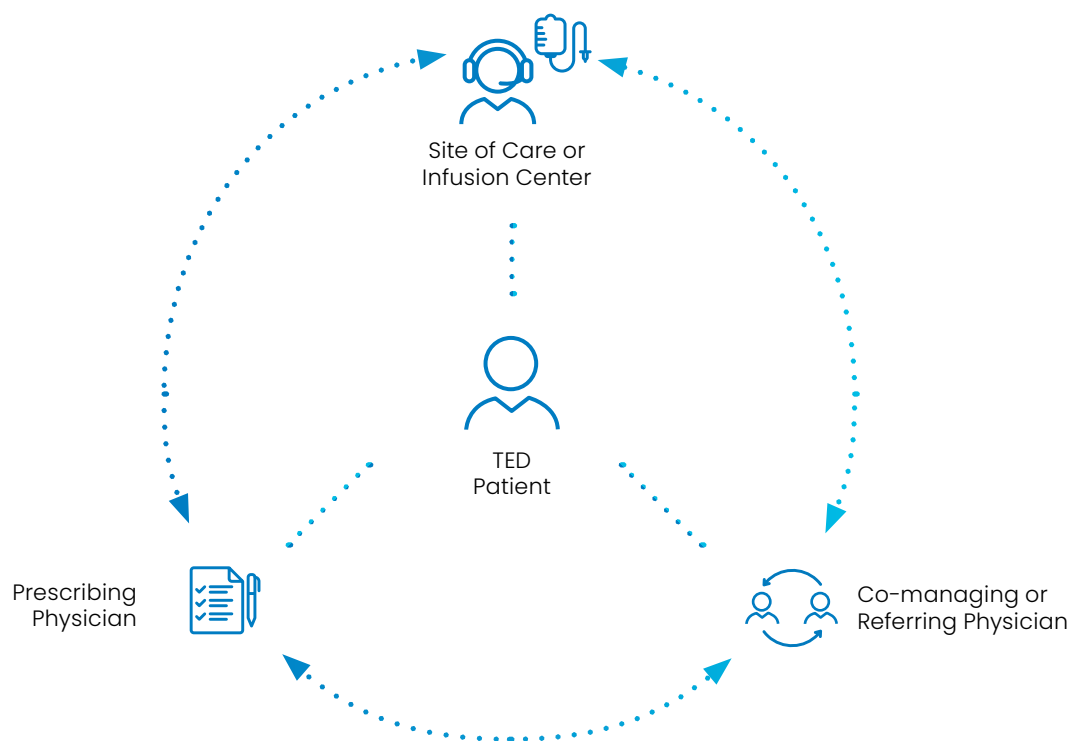
**T3 & T4:** triiodothyronine & thyroxine are the two main hormones produced by the thyroid. They bind to proteins while circulating in the blood and help regulate various bodily functions.

**Unilateral excursion:** range of movement of one (uni-) eye (ocular).

**Xerosis:** dry skin or membranes.



# Clinical Documentation of TED is a Team Effort<sup>7</sup>



**References:** **1.** Barrio-Barrio J, Sabater AL, Bonet-Farriol E, Velázquez-Villoria Á, Galofré JC. Graves' ophthalmopathy: VISA versus EUGOGO classification, assessment, and management. *J Ophthalmol.* 2015;2015:249125. **2.** Wiersinga WM, Perros P, Kahaly GJ, et al. Clinical assessment of patients with Graves' orbitopathy: the European Group on Graves' Orbitopathy recommendations to generalists, specialists and clinical researchers. *Eur J Endocrinol.* 2006;155(3):387-389. **3.** Supplement to: Smith TJ, Kahaly GJ, Ezra DG, et al. Teprotumumab for thyroid-associated ophthalmopathy. *N Engl J Med.* 2017;376:1748-61. **4.** Wang Y, Patel A, Douglas RS. Thyroid eye disease: how a novel therapy may change the treatment paradigm. *Ther Clin Risk Manag.* 2019;15:1305-1318. **5.** Dolman PJ. Grading severity and activity in thyroid eye disease. *Ophthalmic Plast Reconstr Surg.* 2018;34(4S supp 1):S34-S40. **6.** Bahn RS. Graves' ophthalmopathy. *N Engl J Med.* 2010;362(8):726-738. **7.** Burch HB, Perros P, Bednarczuk T, et al. Management of thyroid eye disease: a consensus statement by the American Thyroid Association and the European Thyroid Association. *Thyroid.* 2022;32(12):1-32.