How many of your patients with

# ANCA-ASSOCIATED VASCULITIS (GPA or MPA)

## are presenting with severe active disease?

## SEVERE ACTIVE DISEASE

is more common than you might expect...

Approximately **80% to 90%** of patients with ANCA-associated vasculitis present with **renal or other organ-threatening** manifestations, which can be considered as severe disease[1,2]

For more information on these and other topics, hear from vasculitis experts at ANCA101.com

AMGEN®

ANCA = antineutrophil cytoplasmic antibody.

# Disease Activity and Treatment Toxicity: A Burden for Patient Quality of Life[3]

ONLY ABOUT **25%** of patients are satisfied with their medication's ability to control symptoms while maintaining a good quality of life[4,*]

FOR ABOUT **50%** of patients, even in remission, vasculitis symptoms are debilitating[4,*]

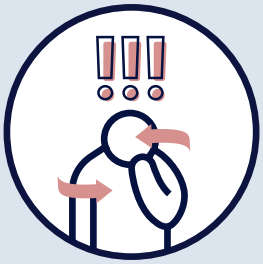

Patients with severe active GPA or MPA experience symptoms that can **negatively impact their quality of life**[5,6]

**QOL in Patients With ANCA-Associated Vasculitis vs. the General Population**

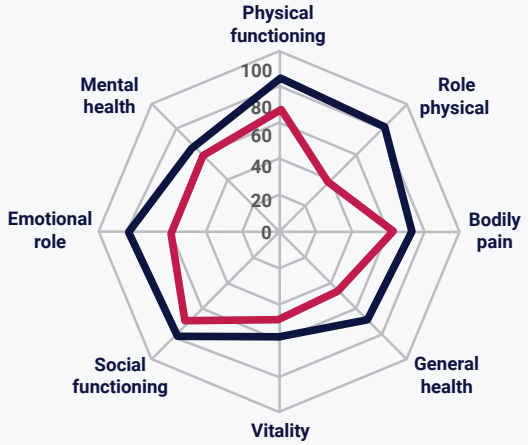


General population (N = 470)[7]

Patients with ANCA-associated vasculitis (N = 410)[7]

Figure adapted with permission from Benarous et al.[8]

## Achieving the Goal of Remission While Reducing the Burden of Treatment Toxicity Can Be Challenging[9]

Even at lower doses, chronic use of glucocorticoids can be associated with toxicity risks[10,11]

*According to an online, self-administered survey of 100 patients with GPA or MPA from July 21-August 25, 2022.[4]
ANCA = antineutrophil cytoplasmic antibody; GPA = granulomatosis with polyangiitis; QOL = quality of life; MPA = microscopic polyangiitis.

# Severe Active GPA and MPA Can Be Challenging to Identify[12-14]

## Careful assessment of heterogeneous symptoms can help[14]

**General**[15,16]
- Myalgia
- Arthralgia/arthritis
- Fever
- Weight loss ≥ 2 kg

**Other**[15,16]
- RBC casts and/or glomerulonephritis

**Cardiovascular**[15,16]
- Loss of pulses
- Valvular heart disease
- Pericarditis
- Ischemic cardiac pain
- Cardiomyopathy
- Congestive cardiac failure

**Mucous membranes/eyes**[15,16]
- Sudden visual loss
- Uveitis
- Blurred vision
- Scleritis
- Episcleritis
- Conjunctivitis
- Blepharitis
- Keratitis
- Retinal changes
- Significant proptosis
- Mouth ulcers
- Genital ulcers
- Adnexal inflammation

**Cutaneous**[15,16]
- Infarct
- Purpura
- Ulcer
- Gangrene
- Other skin vasculitis

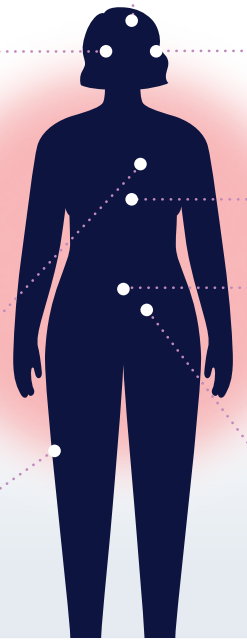

**Ear, nose, & throat**[15,16]
- Bloody nasal discharge/crusts/ulcers/granulomata
- Paranasal sinus involvement
- Conductive hearing loss
- Sensorineural hearing loss
- Subglottic stenosis

**Abdominal**[15,16]
- Peritonitis
- Bloody diarrhea
- Ischemic abdominal pain

**Renal**[15,16]
- Hypertension
- Proteinuria
- Hematuria
- Rise in serum creatinine
- Fall in creatinine clearance

**Nervous system**[15,16]
- Headache
- Meningitis
- Seizures
- Cerebrovascular accident
- Organic confusion
- Spinal cord lesion
- Cranial nerve palsy
- Sensory peripheral neuropathy
- Mononeuritis multiplex

**Chest**[15,16]
- Wheeze
- Nodules or cavities
- Pleural effusion/pleurisy
- Infiltrate
- Endobronchial involvement
- Massive hemoptysis
- Alveolar hemorrhage
- Respiratory failure

**Severe vasculitis** is defined by the American College of Rheumatology/Vasculitis Foundation (ACR/VF) guidelines as having life-threatening or organ-threatening manifestations[1]

**Active disease** represents new, worsening, or **persistent** clinical signs and/or symptoms attributed to GPA or MPA that are not related to prior injury[1]

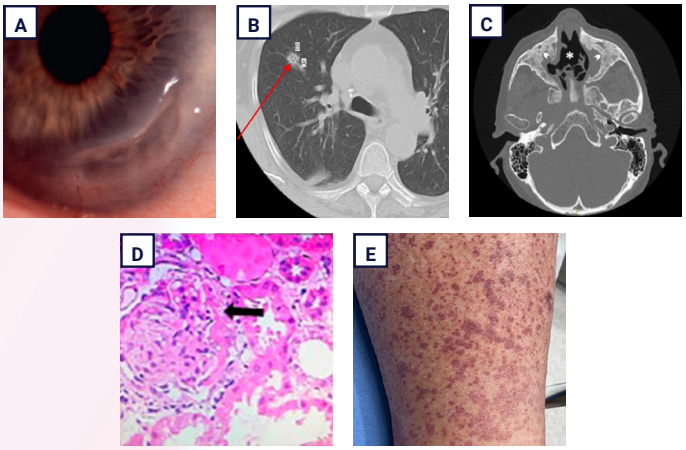


**A.** Peripheral ulcerative keratitis in a patient with GPA[17]

**B.** CT chest showing a right lower lobe 1.2 cm pulmonary nodule (red arrow) in a patient with GPA[18]

**C.** Axial CT scan with anterior septal perforation (asterisk) and maxillary sinus osteitis (arrowheads) in a patient with GPA[19]

**D.** Renal biopsy showing glomerulonephritic fibrocellular crescents (arrow) in a patient with MPA[20]

**E.** Palpable purpura in a patient with GPA[21]

Images used with permission from Macarie et al,[17] Darwich et al,[18] Padoan et al,[19] Zhu et al,[20] and Farrukh et al.[21]

ANCA = antineutrophil cytoplasmic antibody; CT = computed tomography; GPA = granulomatosis with polyangiitis; MPA = microscopic polyangiitis; RBC = red blood cell.

# Challenges to Disease Management Persist

## Patients with severe active GPA or MPA are faced with multiple challenges to disease management[3,9,14,22]

Timely Diagnosis[14]

Achieving Remission[23]

Preventing Relapse[24]

Glucocorticoid Toxicity[25]

Impact on Organ Function[25]

Effect on Quality of Life[5]

## Humoral and alternative complement pathways drive inflammatory vascular injury in GPA and MPA[3,26,27]

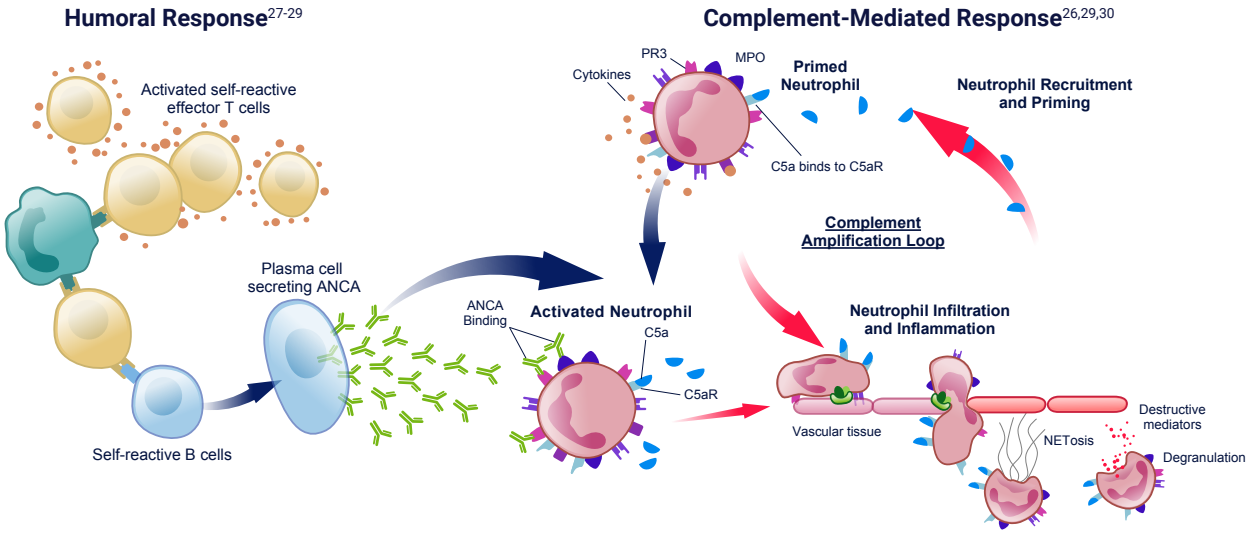


**Opportunities to further care may start with understanding the mechanisms involved in the pathophysiology of GPA and MPA[3,26,27]**

ANCA = antineutrophil cytoplasmic antibody; C5a = complement component 5a; C5aR = complement component 5a receptor; GPA = granulomatosis with polyangiitis; MPA = microscopic polyangiitis; MPO = myeloperoxidase; NET = neutrophil extracellular trap; PR3 = proteinase 3.

# Consider Your Opportunities to Further Care in Severe Active GPA and MPA

## Patients with GPA or MPA often present with severe active disease characterized by heterogeneous manifestations[1,31]

Assessment across multiple organ systems is key to diagnosis[14]

## Despite clinical advances, challenges to disease management persist[3]

Achieving and sustaining remission[23,24]
Treatment toxicity[25]
Impact on organ function[25]
Patient quality of life[4,*]

## Disease management may start by understanding certain mechanisms involved in the pathophysiology of GPA and MPA[3,26]

Opportunities may arise when considering both mechanisms involved in the pathophysiology of GPA and MPA[26,32]

For more information on these and other topics, hear from vasculitis experts at ANCA101.com

## Explore all appropriate disease management options for patients with severe active GPA or MPA

ANCA = antineutrophil cytoplasmic antibody; GPA = granulomatosis with polyangiitis; MPA = microscopic polyangiitis.

*According to an online, self-administered survey of 100 patients with GPA or MPA from July 21, 2022 - August 25, 2022.[4]

1. Chung SA, et al. *Arthritis Rheumatol.* 2021;73(8):1366-1383. 2. Lamprecht P, et al. *Front Immunol.* 2018;9:article 680. 3. Kitching AR, et al. *Nat Rev Dis Primers.* 2020;6(1):71. 4. Data on file, Amgen; 2022. 5. Robson JC, et al. *Patient Relat Outcome Meas.* 2018;9:17-34. 6. Jayne DRW, et al. *N Engl J Med.* 2021;384(7):599-609. 7. Basu N, et al. *Ann Rheum Dis.* 2014;73:207-211. 8. Benarous L, et al. *Clin Exp Rheumatol.* 2017;35(suppl 103):40-46. 9. King C, et al. *Rheumatol Adv Pract.* 2021;5(3):rkab018. 10. McGregor JG, et al. *Clin J Am Soc Nephrol.* 2012;7:240-247. 11. Supplement to: Walsh M, et al. *N Engl J Med.* 2020;382(7):622-631. 12. Hunter RW, et al. *BMJ.* 2020;369:m1070. 13. Qasim A, et al. *StatPearls* [Internet]. StatPearls Publishing; 2023. Accessed March 31, 2023. https://www.ncbi.nlm.nih.gov/books/NBK554372/ 14. Yates M, Watts R. *Clin Med (Lond).* 2017;17(1):60-64. 15. Supplement to: Jayne DRW, et al. *N Engl J Med.* 2021;384(7):599-609. 16. Supplement to: Mukhtyar C, et al. *Ann Rheum Dis.* 2009;68(12):1827-1832. 17. Macarie SS, Kadar A. *Rom J Ophthalmol.* 2020;64(1):3-7. 18. Darwich NS, et al. *J Clin Neph.* 2020;4:1-6. 19. Padoan R, et al. *Vessel Plus.* 2021;5:41. 20. Zhu Y, Zheng X. *Front Oncol.* 2022;12:987507. 21. Farrukh L, et al. *Cureus.* 2023;15(6):e40786. 22. Jain K, et al. *Kidney360.* 2021;2(4):763-770. 23. Stone JH, et al. *N Engl J Med.* 2010;363(3):221-231. 24. Terrier B, et al. *Ann Rheum Dis.* 2018;77(8):1150-1156. 25. Robson J, et al. *Rheumatology.* 2015;54(3):471-481. 26. Chen M, et al. *Nat Rev Nephrol.* 2017;13(6):359-367. 27. Al-Hussain T, et al. *Adv Anat Pathol.* 2017;24(4):226-234. 28. Jennette JC, et al. *Arthritis Rheum.* 2013;65(1):1-11. 29. Shochet L, et al. *Front Immunol.* 2020;11:525. 30. Jennette JC, Nachman PH. *Clin J Am Soc Nephrol.* 2017;12(10):1680-1691. 31. Rowaiye OO, et al. *Clin Kidney J.* 2015;8(3):343-350. 32. Jones RB, et al. *Arthritis Rheum.* 2009;60(7):2156-2168.

© 2023 Amgen Inc. All rights reserved.
10/23 USA-569-80303

AMGEN®